

# FINE-WIRE ELECTROMYOGRAPHIC RECORDING DURING FORCE GENERATION

## Application to Index Finger Kinesiologic Studies<sup>1</sup>

Charles G. Burgar,<sup>2</sup> MD, Francisco J. Valero-Cuevas, PhD and Vincent R. Hentz, MD

**ABSTRACT** Burgar CG, Valero-Cuevas FJ, Hentz VR: Fine-wire electromyographic recording during force generation: application to index finger kinesiologic studies. *Am J Phys Med Rehabil* 1997;76:494-501

When accurately placed, fine-wire electrodes (FWEs) permit selective electromyographic recording during kinesiologic studies; however, their potential to limit contraction of the index finger muscles has not previously been evaluated. Given that these electrodes cannot be reinserted, reliable techniques are necessary to achieve proper placement while minimizing subject discomfort and electrode waste. The small size, close arrangement, and anatomic variability of hand and forearm muscles create challenges to achieving these goals. In this study, we simultaneously measured maximal fingertip forces and fine-wire electromyographic signals from all seven muscles of the index finger. Forces in five directions, with and without FWEs in place, were not statistically different (repeated-measures analysis of variance,  $P < 0.46$ ) in five healthy adult subjects. To guide electrode placement, we identified skin penetration landmarks, direction of needle advancement, and depth of muscle fibers. Fibers of flexor digitorum superficialis and flexor digitorum profundus to the index finger were more distal than depicted in textbooks, requiring electrode placement at or distal to the midpoint of the forearm. For these muscles and the extensor digitorum, locating the desired fibers first with a monopolar needle electrode facilitated subsequent FWE placement. For the dorsal and palmar interossei, lumbrical, and extensor indicis proprius, insertion was aided by concurrent monitoring of the electromyographic signals. We achieved a 93% success rate during FWE placement in a total of 60 muscles. Techniques for recording from each of the seven index finger muscles are described.

**KEY WORDS:** Electromyography Methods, Fine-wire Electrodes, Kinesiology, Biomechanics, Monitoring, Physiologic Methods, Index Finger Muscles

This article describes techniques that improve the accuracy and reliability of fine-wire electromyographic (EMG) studies. Use of the needle insertion

landmarks for muscles described in this article may also improve placement accuracy during procedures such as botulinum toxin injections. EMG recordings using fine-wire electrodes (FWEs) are often used for selective recording of muscle activity in kinesiologic studies, including those of the index finger.<sup>1-5</sup> Previous reports, however, lack sufficient detail to guide electrode placement in all muscles of the index finger, and the effect of indwelling FWEs on maximal voluntary force production has not been established. Electrode insertion methods described in clinical EMG texts<sup>6-8</sup> are not intended for selective recording from extrinsic muscle fibers to specific fingers. The usual approach to lumbrical

**Objectives:** Upon completion of this article, the reader should be able to (1) identify common pitfalls involved in attempting to place electromyographic electrodes into muscles that control the index finger; (2) describe a technique for improving the accuracy of kinesiologic electromyographic recordings from specific muscle fibers; (3) discuss the effect of indwelling fine-wire electrodes on maximal force production in this study. **Level:** Advanced

The Association of Academic Physiatrists is accredited by the Accreditation Council for Continuing Medical Education to sponsor continuing medical education for physicians.

The Association of Academic Physiatrists designates this continuing medical education activity for a maximum of one credit hour in Category 1 of the Physician's Recognition Award of the American Medical Association. Each physician should claim only those hours of credit that he/she actually spent in the educational activity.

\*Disclosure statements have been obtained regarding the authors' relationships with financial supporters of this activity. There is no apparent conflict of interest related to the context of participation of the authors of this article.

0894-9115/97/7606-0494\$03.00/0

AMERICAN JOURNAL OF PHYSICAL MEDICINE & REHABILITATION  
Copyright © 1997 by Williams & Wilkins

Supported by the Rehabilitation Research and Development Service, Department of Veterans Affairs.

<sup>1</sup> From the Veterans Affairs Palo Alto Health Care System, Rehabilitation Research and Development Center, Palo Alto, California, and the Divisions of Physical Medicine and Rehabilitation (C.G.B.) and Hand Surgery (V.R.H.), Department of Functional Restoration, and the Division of Biomechanical Engineering (F.J.V.-C.), Department of Mechanical Engineering, Stanford University, Stanford, California.

<sup>2</sup> All correspondence and requests for reprints should be addressed to: Rehabilitation Research and Development Center (153), VA Palo Alto Health Care System, 3801 Miranda Avenue, Palo Alto, California 94304-1207.

and palmar interosseous muscles is through the sensitive skin of the palm, which may interfere with hand function during recording and is particularly uncomfortable during insertion.

Kinesiologic studies of the index finger muscles using FWEs present special challenges. Positioning the electrodes in specific fibers is often difficult because the muscles may be small in diameter, may be located near fibers of other muscles or adjacent to neurovascular structures, and may have variable anatomy (K. Cole, personal communication, 1995).<sup>9,10</sup> Deep muscles cannot be palpated and must be located using surface landmarks. Selective recording from certain bellies to the index finger is especially difficult with current electrode insertion techniques. Some investigators<sup>11</sup> use a "guided" technique during fine-wire insertion; however, if the wires do not pass through the desired region during initial insertion, it is not possible to withdraw and reposition this type of electrode. An improperly placed FWE must be removed and another attempt made with a new electrode. Rigid-needle electrodes (monopolar or concentric) can be repositioned until they are within the desired fibers, but movement of the recording surface within the muscle during functional tasks may explain the within-study variability previously reported.<sup>12,13</sup> FWEs are anchored within the muscle and usually move with it. In addition, the discomfort produced by muscle contraction with rigid needles in place may prevent maximal effort.

During studies of maximum index finger force generation,<sup>14,15</sup> our initial attempts to place FWEs using standard clinical EMG landmarks<sup>6-8</sup> often failed to achieve adequate selectivity for fibers that exclusively flex or extend the index finger. Even with EMG monitoring during advancement of the inserting needle, as described by Park and Harris,<sup>11</sup> satisfactory recordings were rarely achieved without multiple attempts, each producing discomfort for the subject and requiring a new FWE. We performed the present study to validate new placement approaches that overcome these difficulties and to estimate the effect of FWEs on finger force production. We present these results as an aid to others studying hand biomechanics, as well as to clinicians performing therapeutic injections into index finger muscles.

## MATERIALS AND METHODS

Modifications to clinical EMG insertion techniques were proposed after reviewing relevant anatomic and EMG references. Dissections of four upper limbs from three cadavers, performed with the assistance of an experienced hand surgeon (VRH), led to additional refinements. We found the location of the extrinsic index finger flexor muscle fibers to be more distal than depicted in EMG reference publications. The digastric conformation of the flexor digitorum superficialis to the index

finger<sup>2,9,16</sup> was confirmed. We also identified dorsal approaches to selected intrinsic hand muscles that avoid piercing the palm of the hand and result in little discernible cross-talk. For some muscles, we found it helpful first to locate the desired fibers using a monopolar needle electrode (MNE), and then we followed a similar trajectory while replacing the MNE with a FWE. We validated our electrode placement techniques in ten subjects. In five of these subjects, we studied the effect of indwelling FWEs by measuring maximal voluntary force production before and after placement.

### *Subjects*

Ten healthy right-handed subjects (six females, four males) without evidence of neurologic or orthopedic impairment of the upper limbs participated in this study. The mean age  $\pm$  standard deviation was  $27 \pm 6$  yr. All subjects demonstrated normal isolated control of upper limb muscles, including the ability to produce graded contractions. This study was approved by the Medical Committee for Protection of Human Subjects in Research at Stanford University, and each subject gave written informed consent.

### *Instrumentation*

We fabricated FWEs using a technique adapted from Basmajian<sup>17</sup> and Loeb and Gans.<sup>18</sup> The nylon insulation at one end of stainless steel wires 50 microns in diameter and 150 mm in length (P/N 431, Driver-Harris Co., Harrison, NJ) was removed by passing it quickly through a butane flame. Residue was removed with an alcohol pad. Each wire was trimmed so that 2 mm of conducting surface was exposed. The untrimmed ends of two wires were threaded through the bevel of a stainless steel hypodermic needle (25 mm, 27 gauge or 37 mm, 25 gauge). Folding the trimmed ends of the wires (6 mm of one wire and 3 mm of the other) back along the needle cannula formed barbs with exposed surfaces that did not overlap. We sterilized the electrodes by exposing them to ethylene oxide. Whenever satisfactory placement was likely to require electrode repositioning, we first used disposable monopolar EMG needle electrodes (P/N 902-DMG37, TECA Corporation, Pleasantville, NY), referenced to a surface electrode, to locate the desired fibers. Redux Creme (Hewlett-Packard Medical Products Group, Waltham, MA) served as the electrolyte for reference and ground electrodes.

An eight-channel Viking IIe electromyograph (Nicolet Biomedical, Madison, WI) amplified, filtered, displayed, and provided auditory output of the EMG signals. We visually monitored the raw EMG signals for artifact. A 100 Hz-20 kHz band-pass filter minimized artifact and enhanced selectivity. Full-wave rectification and smoothing (20 ms

time constant) using custom analog circuits produced the envelope of the EMG signal, which was digitized at 200 samples/s and stored using an Apple Macintosh computer with an analog-to-digital interface and data acquisition software (NB-MIO-16 and LabVIEW, National Instruments, Austin, TX).

We measured fingertip forces against the low-friction surface of a three-axis transducer (130 N maximum, 0.1 N resolution; F/T Gamma, Assurance Technologies, Garner, NC) mounted on the end of a robotic arm (Puma 260, Stäubli-Unimation, Inc., Duncan, SC). The robot was preprogrammed to position the transducer rapidly and accurately to measure force in each of five directions. To increase comfort and prevent generation of significant shear forces between the fingertip and the transducer, subjects wore custom-fit plastic thimbles on the end of the index finger, with 5-mm ball bearings imbedded in the outer contact surfaces.

### Experimental Design

Subjects were asked to generate a complete series of finger force measurements without EMG monitoring and then again the following day while EMG activity was recorded. The finger was maintained in neutral ad-abduction, 45° flexion at metacarpophalangeal (MCP) and proximal interphalangeal (PIP) joints and 10° flexion at distal interphalangeal joints, with the wrist in full extension and neutral radial deviation and the index finger not resting against the middle finger. Video monitoring ensured replication of finger and hand test postures. Under each test condition, subjects were instructed to generate the maximum possible index finger force perpendicular to the surface of the transducer. Additional details of the testing apparatus and finger postures have been described by Valero-Cuevas.<sup>14, 15</sup>

### Electrode Placement

Skin penetration occurred under aseptic conditions. During electrode placement and verification of signal quality, subjects lay supine on an examining table. They were instructed to report unexpected pain or sensations. Local anesthetic agents were not used. No adverse effects, other than occasional mild local discomfort lasting 2 days, were reported. After electrode insertion into muscles of the right upper limb, subjects moved to the force measurement workstation, where they sat in a chair with their forearm resting in a trough and their right hand gripping a vertical dowel. In two subjects, we validated our method of electrode placement only in the extrinsic flexor muscles of the index finger. In the remaining eight subjects, we targeted all seven muscles of this digit. Electrodes typically remained in place for 1.5–2 h. At the beginning and end of each session, we tested each EMG channel to verify its response and selectivity. The surface landmarks, needle trajectory, and methods for confirming accu-

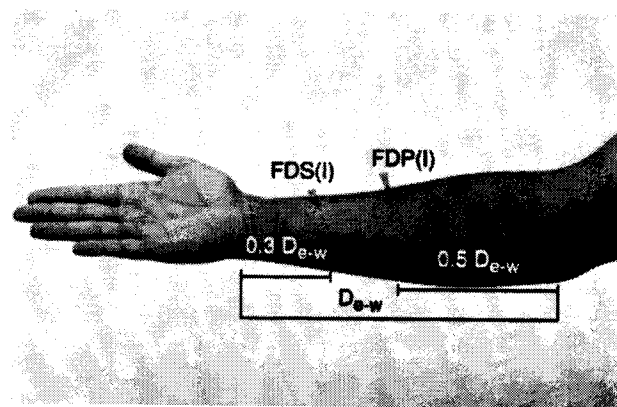
rate and selective EMG recording are described for each of these muscles.

### *Flexor Digitorum Superficialis (FDS) Fibers to Index Finger (FDS(I))*

Detailed descriptions of the anatomy of the finger muscles can be found in standard textbooks, such as *Gray's Anatomy*.<sup>12</sup> The structure of the FDS(I), in particular, must be appreciated for reliable targeting of the muscle's specific bellies. The FDS originates in the proximal forearm as two heads, and its fibers lie in two planes. Those arising from the radius lie in a superficial plane to connect with the tendon to the middle finger. The tendon to the ring finger originates from fibers in the superficial plane that arise from the common flexor tendon, as well as from fibers arising from an intermediate tendon. Brand and Hollister<sup>9</sup> described a fusiform muscle belly arising proximally from the common flexor tendon and inserting on an intermediate tendon that, in turn, serves as the origin for muscle bellies to the ring, little, and index fingers. The muscle fibers and tendons to the latter two fingers lie in the deeper plane of the FDS and may be found in the distal half of the forearm. This feature is not generally illustrated in clinical EMG texts. Important variations occur in the origin and interconnections of the individual muscle bellies.<sup>2, 16</sup>

### Electrode Placement Technique

We identified the tendons of the superficial flexor group in the distal half of the forearm and measured the distance between the elbow crease and the distal wrist crease. We first inserted a MNE over the lateral (radial) border of the ulna, just medial to the flexor carpi radialis tendon and proximal to the distal wrist crease by 30% of the distance between the creases (Fig. 1). The electrode was angled to-



**Figure 1.** Fine-wire electrode insertion into flexor digitorum superficialis fibers to the index finger (FDS(I)) occurred at a point proximal to the distal wrist crease by approximately three-tenths of the distance to the elbow crease ( $D_{e-w}$ ). The electrode inserted into flexor digitorum profundus fibers to the index finger (FDP(I)) was placed near the midpoint of the  $D_{e-w}$ .

ward the medial border of the radius and was advanced while monitoring the audio produced by EMG activity. Slight, rapid flexion and extension of all digits, alternating with similar movement by only the index finger, provided a "homing signal" to guide electrode placement and helped detect contact with tendons, thus avoiding their penetration. We repositioned the electrode tip, as necessary, to produce crisp, loud bursts of EMG activity synchronous with index finger PIP joint flexion. The depth of penetration was typically 10–20 mm. After comparing their relative lengths, we inserted a FWE parallel to the MNE and advanced it until the bare recording surfaces of the wires were at approximately the same depth as the tip of the MNE. Once a satisfactory signal was obtained from the FWE, we removed the MNE and the FWE insertion needle, leaving only the fine wires in place.

We considered the placement satisfactory when strong resisted flexion of the index finger PIP joint produced a full interference pattern (oscilloscope baseline obscured by motor unit action potentials) but resisted flexion of all other joints of the hand produced no discernible potentials.

### Pitfalls

Whenever tingling or an electrical sensation in the hand was reported, the electrode should be slightly withdrawn and reoriented before further advancement to avoid piercing the median nerve. If inserted medial to the FDS(I), the electrode will enter the slip to the little finger. If inserted too deep, the electrode will enter the flexor digitorum profundus (FDP) or pronator quadratus. Too lateral a placement targets the flexor pollicis longus.

### FDP Fibers to Index Finger (FDP(I))

Like the FDS, the FDP ends in four tendons, one to each finger. The fibers to the index finger often form a separate belly throughout most of the forearm, whereas formation of the other finger tendons occurs at more variable levels.

### Electrode Placement Technique

We entered the fibers of FDP(I) in a manner similar to that described for placement within FDS(I). We inserted a MNE over the medial border of the radius at one-half the distance between the elbow crease and the distal wrist crease (Fig. 1). While monitoring the EMG audio, the electrode was advanced perpendicular to the skin or angled slightly toward the ulna, passing through the flexor carpi radialis to a depth of approximately 30 mm. The index finger was held in light resisted flexion at the distal interphalangeal joint and the electrode was repositioned until located within active fibers. After

satisfactory positioning, the MNE served as a guide for inserting a FWE and was then removed.

We verified adequate placement by observing EMG responses during sequential flexion of each joint of the wrist, thumb, and fingers, while stabilizing all other joints in extension.

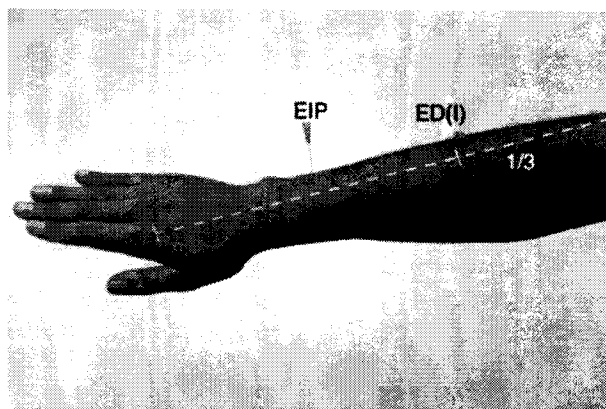
### Pitfalls

When placing electrodes in large forearms, we found it necessary to use 50-mm monopolar and fine-wire insertion needles to reach the FDP. The median nerve typically lies between the FDS and FDP in the midforearm and care should be taken to avoid its penetration. The flexor pollicis longus, radial artery, and superficial radial nerve lie lateral to the insertion site. The interosseous membrane, nerve, and artery lie deep to FDP(I). If inserted too superficially, the electrode will be in the flexor carpi radialis the electrode or FDS. If it is too medial, it will enter the FDP belly to the middle finger.

### *Extensor Indicis Proprius*

#### Electrode Placement Technique

The anatomy of the extensor indicis proprius permits FWE placement without the need for fiber localization with a MNE. Our approach followed common clinical EMG guidelines.<sup>8</sup> We inserted the FWE needle between the ulna and the tendons of the finger extensor muscles, 40–50 mm proximal to the ulnar styloid (Fig. 2). The EMG audio was monitored and the index finger was maintained in extension against minimal force while the electrode was advanced into actively firing motor fibers. The recording contacts were typically 5–15 mm beneath the skin surface.



**Figure 2.** Fine-wire electrode insertion into the extensor indicis proprius (EIP) was performed using common clinical landmarks. Insertion into the extensor digitorum fibers to the index finger (ED(I)) occurred along and at the junction of the proximal and middle thirds of a line between the lateral epicondyle and the knuckle of the index finger.

A full interference pattern during resisted index finger extension and electrical silence during resisted extension of the thumb and other fingers indicated successful placement.

### Pitfalls

Placement within the muscle fibers of the extensor pollicis longus or extensor pollicis brevis can occur if the insertion is too proximal or radial. Care should be taken not to penetrate the extensor carpi ulnaris or extensor digiti minimi tendons, which lie medial and lateral to the typical insertion trajectory. Alternating flexion and extension of the little finger should not cause movement of the hypodermic needle.

### *Extensor Digitorum Fibers to Index Finger (ED(I))*

#### Electrode Placement Technique

Although the ED(I) is superficial and can often be easily palpated, we employed a MNE for localization because of the frequent presence of EMG signals from extensor digitorum fibers to the middle finger. We inserted the electrode perpendicular to the skin, along the line connecting the lateral epicondyle and the knuckle of the index finger, at one-third of the distance of this line (Fig. 2). The electrode was advanced to a depth of 10–30 mm while monitoring for activity caused by slight extension of the index finger. If activity was present on extension of the wrist or other fingers, the electrode was withdrawn and redirected. If activity isolated to index finger extension was not found, the electrode was removed and reinserted 10–20 mm distally. If tendon was encountered, the electrode was repositioned proximally. When the MNE recording was satisfactory, we replaced the MNE with a FWE.

Placement was successful when a full interference pattern was obtained during resisted index finger MCP extension with electrical silence during resisted extension of the other fingers and of the wrist.

### Pitfalls

During wrist extension to test for cross-talk from extensor carpi radialis, simultaneous flexion of the index finger MCP joint was often necessary to minimize contraction of ED(I). We employed a similar technique, using simultaneous flexion of index finger MCP and extension of middle finger MCP joints, when testing for absence of EMG activity from middle finger fibers.

### *First Dorsal Interosseous*

#### Electrode Placement Technique

We placed FWEs into the first dorsal interosseous following the common clinical EMG approach and without first using a MNE. We passed the FWE

through the dorsum of the hand, just radial to the midpoint of the second metacarpal bone (Fig. 3). The index finger was abducted against minimal resistance, the EMG audio was monitored, and the wire tips were advanced to a typical depth of 5–10 mm.

A full interference pattern during resisted index finger abduction and electrical silence during slight simultaneous adduction of the thumb and index finger indicated a successful placement.

### Pitfalls

Too lateral an approach results in placement of the FWE in the adductor pollicis.

### *First Palmar Interosseous (1st PI)*

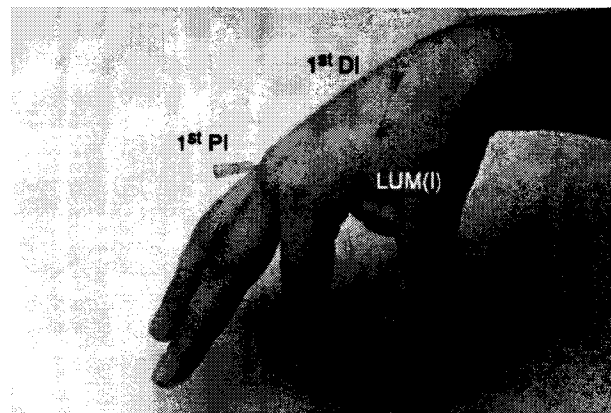
#### Electrode Placement Technique

We inserted a FWE through the dorsal hand surface between the knuckles of the second and third digits, in a proximal and radial direction, toward the ulnar border of the second metacarpal bone (Fig. 3). The needle was angled 30°–45° to the skin surface. A mild resistance to adduction of the index toward the middle finger was maintained and the electrode was advanced until the EMG signal indicated that the electrode was positioned within fibers of the 1st PI.

To ensure freedom from cross-talk from lumbrical and dorsal interosseous muscles, the EMG activity during adduction was compared with signals generated during weak index finger MCP joint flexion with interphalangeal joint extension and during radial movement of the middle finger toward the thumb.

### Pitfalls

If placed superficially, the FWE may record from the second dorsal interosseous muscle. If the FWE is



**Figure 3.** Fine-wire electrode insertion into the index finger intrinsic muscles. See text for landmarks. 1<sup>st</sup> PI = first palmar interosseous; 1<sup>st</sup> DI = first dorsal interosseous; LUM(I) = first lumbrical.

angled in an ulnar direction, the second palmar interosseous may be entered.

### First Lumbrical

#### Insertion Technique

We avoided penetration of the glabrous (hairless) skin of the palm because electrodes inserted through this surface can interfere with grip and cause unnecessary pain. Instead, we employed a subcutaneous approach from the first web space (Fig. 3). Palpation of the belly of the first lumbrical during resisted forceful 90° MCP joint flexion, while interphalangeal joint extension was maintained, permitted a target location to be identified where this muscle crosses the transverse palmar crease (slightly radial to the flexor tendons). The needle was inserted 5–10 mm proximal to the radial end of the same palmar crease, parallel to the skin surface, until within the fibers of the first lumbrical.

Recruitment of EMG activity during MCP flexion and silence during isolated index finger abduction and thumb adduction confirmed proper positioning.

#### Pitfalls

Palmar distraction of the skin of the web space helped avoid first dorsal interosseous penetration.

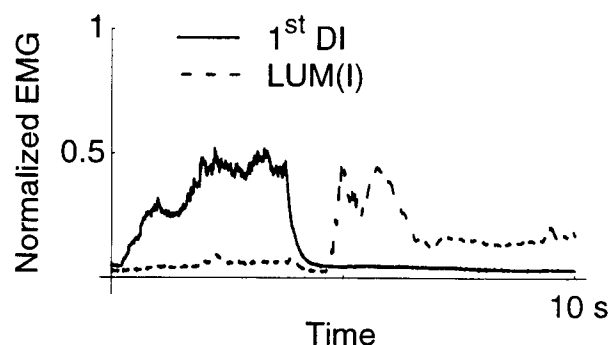
## RESULTS

### Selective EMG Recording

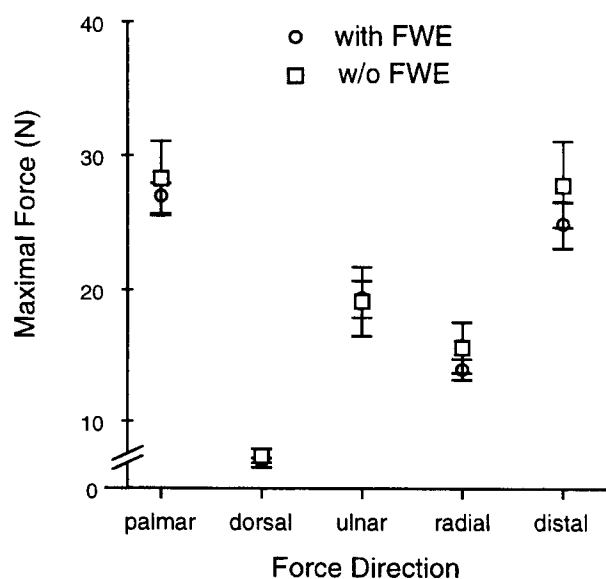
We attempted to record from all seven muscles of the index finger in each of eight subjects and from the FDS(I) and FDP(I) in two additional subjects (a total of 60 muscles). Fine-wire EMG recording of activity isolated to the intended muscle fibers was achieved for 93% of the target sites. Figure 4 demonstrates the typical levels of cross-talk and artifact observed. Reliable data was unobtainable from four sites. The desired signal could not be obtained without significant cross-talk in one FDP and one FDS, apparently due to interdigitation of fibers to the middle finger. One electrode was removed in mid-experiment from the 1st PI because of pain and reduced signal amplitude. The electrode intended for the 1st PI recorded activity primarily from the second dorsal interosseous in one subject. The signal from a fifth electrode, for the FDS(I), was usable but cross-talk from the middle finger fibers of the FDS could not be completely eliminated. We occasionally experienced a loss of signal while advancing the FWE, probably due to contact between the bare wire tips and the metal needle. Slight rotation of the needle shaft usually restored the signal.

#### Effect of Indwelling FWEs on Force Production

The results of repeated force measurements, with and without the FWEs in place, are shown in Figure



**Figure 4.** Simultaneous recordings showing typical cross-talk between first dorsal interosseous (1<sup>st</sup> DI) and first lumbrical (LUM(I)) during sequential resisted radial abduction, followed by isolated flexion of the metacarpophalangeal joint. The index finger remains extended at the proximal interphalangeal and distal interphalangeal joints. EMG = electromyographic.

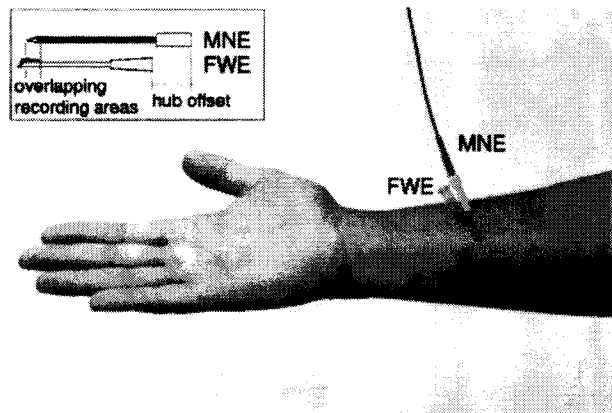


**Figure 5.** Adjusted mean ( $\pm$  SE) finger force magnitudes with and without fine-wire electrodes (FWEs) in place. Forces emanate from the midpoint of and perpendicular to the distal phalanx of the index finger in palmar, dorsal, ulnar, and radial directions. Distal force is axially aligned with the distal phalanx. Maximal static finger forces showed no statistically significant change with the presence of the electrodes ( $P < 0.46$ ).

5. According to repeated-measures analysis of variance, the presence of FWEs during force measurements did not significantly alter index finger force magnitudes ( $P < 0.46$ ), but the magnitudes did vary with direction of force generation ( $P < 0.05$ ).

## DISCUSSION

Placement of the FWEs and contraction of muscles during force measurement were generally well tolerated. Only one electrode caused discomfort that became intolerable. The reduction of signal ampli-



**Figure 6.** A monopolar needle electrode (MNE) serves as the guide for subsequent fine-wire electrode (FWE) placement. Comparing the lengths of the needle shafts and the respective recording surface locations before use (see insert) facilitates placement within the same muscle fiber territory.

tude accompanying the pain was believed to indicate local intramuscular bleeding, so that electrode was removed. Although it was typically necessary to reposition the needle into several locations while seeking an acceptable signal, initial fiber localization with a MNE was tolerated without complaint and was preferred to multiple FWE insertions. For the FDS, FDP, and extensor digitorum, initial use of a MNE allowed the EMG signal to be sampled and, if necessary, the electrode to be withdrawn and redirected into another area. This technique may be employed any time the success of a single FWE insertion is uncertain. If placement is suboptimal, FWEs can only be advanced further (assuming the hypodermic needle is still in place); withdrawal of the needle used to place FWEs leaves the wire tips imbedded in the tissue. With the use of aseptic technique, it is common clinical practice to use one disposable MNE for multiple insertions in an individual patient. A concentric needle electrode could also be used to locate target areas. It was helpful to compare the configuration of the fine-wire and monopolar needles before insertion so the recording surfaces of the electrodes could be placed at an equal depth (Fig. 6).

The difficulty encountered in FDS(I) recording can be accounted for by the anatomic and functional complexity of this muscle. The ability independently to flex the PIP joint of each finger stems from the subdivision of the FDS into slips controlling each finger. However, a proximal, common belly contributes to flexion of the index, ring, and, frequently, little fingers through an intermediate tendon, as described above. Activity recorded by electrodes inserted into the common belly may not be specific for flexion of a single digit. We found the distal bellies of FDS to be thin in some cadavers. Successful placement of both electrode wire tips within one belly would depend, in such cases, on

the angle at which the needle enters the muscle. The method used to record from the FDS(I) in this study differs from previous approaches and resulted in a high success rate. The digastric configuration of this portion of the muscle and the anatomic variability present a challenge to electrode placement. We compensated for these factors by inserting the FWE more distally (in the belly directly attached to the index finger tendon) and by conducting a search for the target fibers with a MNE before FWE placement.

For the FDP(I), electrode insertion from the ulnar aspect of the forearm, as recommended by others,<sup>8</sup> requires a longer needle to reach the fibers to the index finger than a volar approach. Medial insertion is also more likely to result in the placement within portions of the muscle that flex other fingers. In our subjects, the fibers attached to the index finger were segregated in the midforearm, allowing selective recording from FDP(I). Attempts at more proximal placements usually yielded significant activity with flexion of other digits.

Listening to the raw EMG audio during electrode insertion provided continuous guidance and an indication of adequate placement. Electrical stimulation through the electrode while mechanical response is observed may offer certain advantages;<sup>19</sup> however, we find it less useful for predicting EMG cross-talk in the recorded signal. It is possible to obtain the advantages of both methods by using a switch to alternate rapidly between stimulating and recording through the electrode.<sup>20</sup>

The ability to detect activation of functional groups of muscle fibers may be a useful tool for improving models of musculoskeletal force generation and neuromuscular coordination. Enhanced recording accuracy may also facilitate clinical assessment of gait impairment and of movement disorders.

## CONCLUSIONS

This study demonstrates the feasibility of simultaneously measuring maximal voluntary fingertip force generation and EMG activity without significant influence from indwelling FWEs in all seven muscles of the index finger. The FWE placement methods described in this article provided a high level of accuracy and reliability. The use of EMG audio monitoring and initial fiber location with a semirigid electrode may be applicable to EMG recording from other muscles as well.

## ACKNOWLEDGMENT

We appreciate the assistance of M. Elise Johanson, MS, PT, in placing some of the fine-wire electrodes.

## REFERENCES

1. Boivin G, Wadsworth GE, Landsmeer JMF, Long C: Electromyographic kinesiology of the hand: muscles driving the index finger. *Arch Phys Med Rehab* 1969;50:17-26.
2. Close JR, Kidd CC: The functions of the muscles of the thumb, the index, and long fingers: synchronous recording of

motions and action potentials of muscles. *J Bone Joint Surg Am* 1969;51:1601-1620.

3. Darling WG, Cole KJ: Muscle activation patterns and kinetics of human index finger movements. *J Neurophysiol* 1990;63:1098-1108.

4. Darling WG, Cole KJ, Miller GF: Coordination of index finger movements. *J Biomech* 1994;27:479-491.

5. Long C, Conrad PW, Hall EA, Furler SL: Intrinsic-extrinsic muscle control of the hand in power grip and precision handling: an electromyographic study. *J Bone Joint Surg Am* 1970;52:853-867.

6. Goodgold J: *Anatomical Correlates of Clinical Electromyography*. Baltimore, Williams & Wilkins, 1984.

7. Chu-Andrews J, Johnson RJ: *Electrodiagnosis: An Anatomical and Clinical Approach*, Philadelphia, Lippincott, 1986.

8. Perotto AO: *Anatomic Guide for the Electromyographer: The Limbs and Trunk*, ed 3. Springfield, Charles C. Thomas, 1994.

9. Brand P, Hollister A: *Clinical Mechanics of the Hand*, ed 2. St. Louis, Mosby Year Book, 1993.

10. Williams PL: *Gray's Anatomy: The Anatomical Basis of Medicine and Surgery*, ed 38. New York, Churchill Livingstone, 1995.

11. Park TA, Harris GF: "Guided" intramuscular fine wire electrode placement: a new technique. *Am J Phys Med* 1996;75:232-234.

12. Maier MA, Hepp-Reymond MC: EMG activation patterns during force production in precision grip. Part I. Contribution of 15 finger muscles to isometric force. *Exp Brain Res* 1995;103:108-122.

13. Maier MA, Hepp-Reymond MC: EMG activation patterns during force production in precision grip. Part II. Muscular synergies in the spatial and temporal domain. *Exp Brain Res* 1995;103:123-136.

14. Valero-Cuevas FJ: *Identification of Biomechanical Factors Limiting Finger Force Production*. Doctoral dissertation. Mechanical Engineering Department, Biomechanical Engineering Division. Stanford, Stanford University, 1997.

15. Valero-Cuevas FJ, Burgar C, Zajac FE, Hentz VR, McGill KC, An KN: Muscle coordination during maximal index-finger ad-abduction forces (abstract). *The 26th Annual Meeting of the Society for Neuroscience*, Washington, DC, 1996.

16. Agee J, McCarroll HR, Hollister AM: The anatomy of the flexor digitorum superficialis relevant to tendon transfers. *J Hand Surg [Br]* 1991;16:68-69.

17. Basmajian JV, De Luca CJ: *Muscles Alive: Their Functions Revealed by Electromyography*, ed 5. Baltimore, Williams & Wilkins, 1985.

18. Loeb GE, Gans C: *Electromyography for Experimentalists*. Chicago, University of Chicago Press, 1986.

19. Geenen C, Consy E, Ashby P: Localizing muscles for botulinum toxin treatment of focal hand dystonia. *Can J Neurol Sci* 1996;23:194-197.

20. Burgar CG, Valero-Cuevas FJ: Improved targeting of long index finger flexors during chemodeneration (abstract). *Arch Phys Med Rehabil* 1996;77:985.

---

#### How to Obtain CME Category 1 Credits

To obtain CME Category 1 credit, this educational activity must be completed and postmarked by December 31, 1998. Participants may read the articles and take the exams issue by issue or wait to study several issues together. After reading the three CME Articles in this issue, participants may complete the Self-Assessment Exam by answering the questions on the CME Answering Sheet and the Evaluation pages, which appear later in this section. Send the completed forms to: CME Department, Association of Academic Physiatrists, 5987 E. 71st Street, Suite 112, Indianapolis, IN 46220. Documentation can be received at the AAP National Office at any time throughout the year, and accurate records will be maintained for each participant. CME certificates are issued only once a year in January for the total number of credits earned during the prior year.